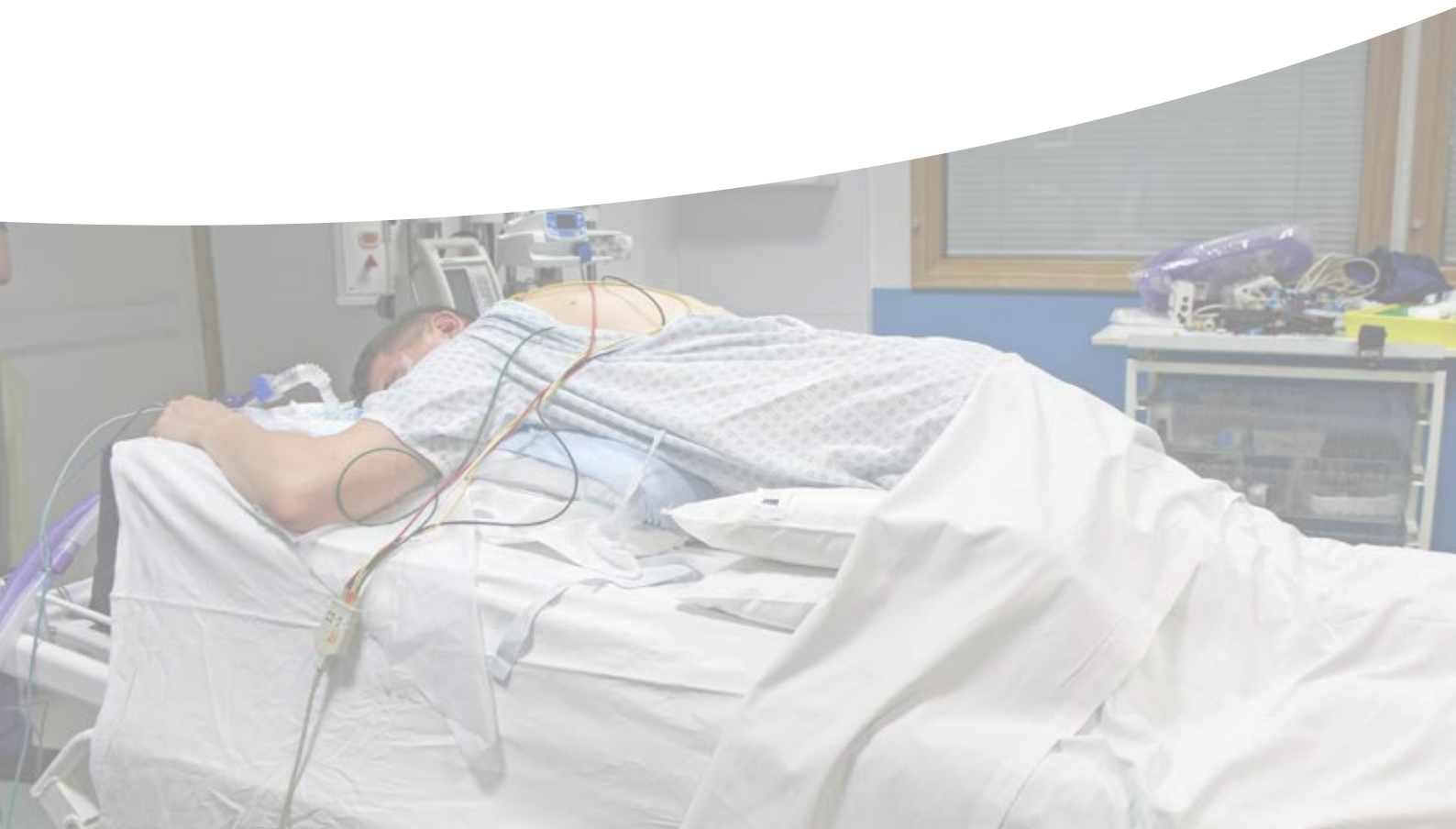

Guidance For:

Prone Positioning in Adult Critical Care



Guidance For: Prone Positioning in Adult Critical Care

1. Introduction	5
2. LocSSIP for Proning in Critical Care	7
3. Proning Protocol	9
a. Indications	9
b. Contraindications	9
c. Equipment	10
d. Preparation	10
4. Procedures	12
a. Supine to Prone	12
b. Prone to Supine	19
5. Nursing guidance for maintaining the patient in the prone position to prevent complications	20
6. Special Circumstances	23
a. Prone positioning on ECMO	23
b. Flexible Bronchoscopy in the Prone Position	25
7. Cardiac arrest in the prone position	27
Chest Compressions	27
Defibrillation	28
Appendix 1.	
LocSSIP for Proning in Critical Care	31
Appendix 2.	
Post Proning Nursing Checklist	33
Appendix 3.	
Prone Cardiac Arrest Flowchart	35

Guidance For: Prone Positioning in Adult Critical Care

Prepared on behalf of the Intensive Care Society and Faculty of Intensive Care Medicine by:

Dr Peter Bamford – Consultant in Intensive Care Medicine and Anaesthesia, Countess of Chester NHS Trust

Dr Craig Denmade – ST9 Intensive Care Medicine and Acute Medicine, Liverpool University Hospitals NHS Foundation Trust

Mrs Christine Newmarch – Senior Sister, Liverpool University Hospitals NHS Foundation Trust

Dr Peter Shirley – Consultant in Anaesthesia and Critical Care Medicine, Royal London Hospital

Dr Ben Singer – Consultant in Critical Care and Anaesthetics, Barts Heart Centre, Consultant in Pre-hospital Care, Barts NHS Trust and London's Air Ambulance

Dr Stephen Webb – Consultant in Anaesthesia and Critical Care, Royal Papworth Hospital

Dr David Whitmore – Consultant in Intensive Care Medicine and Anaesthesia, Countess of Chester NHS Trust

Disclaimer:

Neither the Intensive Care Society, Faculty of Intensive Care Medicine nor the authors accept any responsibility for any loss or damage arising from actions or decisions based on the information contained within this publication. Ultimate responsibility for patient safety with regards to the treatment of patients and the interpretation of the published material lies with the attending physician. The opinions expressed are those of the authors and the inclusion in this publication of material relating to a particular product or method does not amount to an endorsement of its value, quality, or the claims made by the manufacturer.

Published date: November 2019

Review date: November 2022

1. Introduction

Over the last two decades randomised controlled trials have consistently demonstrated that oxygenation can be significantly improved in patients with acute respiratory distress syndrome (ARDS) when ventilated in the prone position. ⁽¹⁻⁵⁾ Early trials of prone ventilation failed to demonstrate any impact on mortality, although these trials were conducted in an era prior to lung protective ventilation, often had patients prone for short periods and included patients with mild ARDS. ^(1,2) As trial design evolved to include modern ventilation practices along with patients with more severe ARDS, evidence emerged that the early application of prolonged prone positioning may significantly decrease mortality compared to conventional supine ventilation. ⁽⁵⁾

This stance has been further supported by a recent meta-analysis that concludes mechanical ventilation in the prone position significantly reduces mortality in patients with moderate to severe ARDS when used early and for greater than 16 hours per day in patients receiving lung protective ventilation. ⁽⁶⁾ In addition, a Cochrane systematic review published in 2015 recommends that prone ventilation for 16 or more hours per day should be actively considered in patients with severe hypoxaemia within 48 hours of mechanical ventilation. ⁽⁷⁾ This has also led to the inclusion of prone ventilation in the ARDS guidance published by the Intensive Care Society (ICS) and Faculty of Intensive Care Medicine (FICM). ⁽⁸⁾

These recommendations would suggest the use of early prone ventilation for moderate to severe hypoxaemia and potentially an increase in the number of patients that should be considered for proning. The increase in use of the prone position in critical care may have been partially responsible for a spike in critical incidents reported to NHSi over recent years. At the end of 2017, NHSi approached the ICS/FICM Joint Standards Committee (JSC), keen to draw our attention to this increase in incidents and with the hope that the committee might identify a strategy to reduce the number of incidents moving forward.

With this in mind the ICS/FICM JSC performed a national survey of its members to identify current practices across the UK and to identify whether there was a need for a national guidance on managing patients in the prone position.

The survey confirmed that 80% of respondents would routinely prone a patient with refractory hypoxia, intimating that there has been widespread acceptance of prone ventilation as a treatment strategy in these circumstances. Interestingly the survey identified that only 30% of respondents worked within a unit that used a specific prone ventilation protocol/checklist to facilitate the procedure of turning a patient prone. Only 58% of units used a post-proning protocol or guidance regarding how to nurse patients in this often, unfamiliar position. Surveyed members reported personal experience with wide array of complications including;

- Pressure sores (most cited injury)
- Facial / periorbital oedema
- IV line / ETT displacement
- CVS instability
- Ocular injury/corneal abrasions
- Brachial plexus injury
- Staff injury
- CRRT line flow problems

Most of these complications are preventable and it is hoped that the adoption of the guidance set out within this document will help improve safety and reduce complications associated with the prone positioning of mechanically ventilated patients. This document also hopes to standardise the approach to managing a cardiac arrest in the prone position, and has some guidance on prone ventilation in ECMO patients as well as considerations for performing bronchoscopy in the prone position. Assuming adequate staffing and equipment is available, the intervention of prone positioning involves very low costs and provided additional patient complications and long-term injuries to staff do not occur, would almost certainly be a cost-effective intervention. ⁽⁷⁾

References

1. Gattinoni, L., Tognoni, G., Pesenti, A. et al. Effect of Prone Positioning on the Survival of Patients with Acute Respiratory Failure. *N Engl J Med* (2001); 345 (8): 568-573.
2. Geurin, C., Gaillard, S., Lemasson, S. Effects of Systematic Prone Positioning in Hypoxaemic Acute Respiratory Failure. *JAMA* (2004); 292: 2379-2387.
3. Mancebo, J., Fernández, R., Blanch L. et al. A Multicenter Trial of Prolonged Prone Ventilation in Severe Acute Respiratory Distress Syndrome. *Am J Respir Crit Care Med* (2006); 173: 1233–1239.
4. Taccone, P., Pesenti, A., Latini, R. et al. Prone–Supine II Study Group. Prone Positioning in Patients with Moderate and Severe Acute Respiratory Distress Syndrome: A Randomized Controlled Trial. *JAMA* (2009); 302: 1977–1984.
5. Guérin, C., Reignier, J., Richard, JC. Et al. PROSEVA Study Group. Prone Positioning in Severe Acute Respiratory Distress Syndrome. *N Engl J Med* (2013); 368: 2159–2168.
6. Sud, S., Friedrich, J., Adhikari, N. et al. Effect of prone positioning during mechanical ventilation on mortality among patients with acute respiratory distress syndrome: a systematic review and meta-analysis. *CMAJ* (2014); 186 (10): 381-390.
7. Bloomfield, R., Noble, D., Sudlow, A. (2015) Prone position for acute respiratory failure in adults. *Cochrane database of systematic reviews*. CD008095.pub2
8. Guidelines on the management of the Acute Respiratory Distress Syndrome. Version 1 July 2018. Faculty of Intensive Care Medicine and Intensive Care Society.

2. LocSSIP for Proning in Critical Care

Local safety standards for invasive procedures (LocSSIPs) have been developed across the country following the NHS England publication of the National Safety Standards for Invasive Procedures (NatSSIPs) document ⁽¹⁾. The primary focus of a units' LocSSIP documentation is to improve patient safety for invasive procedures ⁽²⁾.

Although turning a patient into the prone position is not an invasive procedure, it is complex and has many potential complications. It is therefore appropriate to apply the same standard of care to proning a patient as we do to the other procedures performed within the critical care environment. As a result, this guidance document recommends that units should use a WHO style checklist to enhance patient safety. Complications should be reduced if a systematic framework for performing the procedure is developed within a unit. The checklist is designed to improve communication between team members carrying out the procedure. Identifying roles and responsibilities and creating a culture where team members have the autonomy to speak out if they identify any problems, should also help to reduce the frequency of complications.

Vital to the success of a LocSSIP is the governance surrounding the reporting of complications during the proning or de-proning of a patient. All complications should be logged and recorded locally, with regular review of practice taking place to ensure the safety lessons learned are implemented within the department.

Education is the final element of a successful LocSSIP. Units need to ensure their staff stay up to date with training in how to prone patients, especially as the procedure is likely to be increasingly performed on Intensive Care Units. This may be done through regular manual handling training, SIM training or through regular practice drills on an individual unit.

We have included an example of a LocSSIP style checklist in Appendix 1 of this guidance. However, it should be noted that these checklists are intended to be unit-specific and therefore should be regularly updated in response to safety issues that have been highlighted at a particular unit.

The core components should however not change and the following should be included:

Pre-Procedure Check

- All members of the team will introduce themselves at this stage and allocate roles
- The specific pre-procedural checks each unit has determined to be important can be addressed with the appropriate responses from the team depending on their assigned roles.

Timeout

- Essential pre-procedural checks are performed at this stage
- Essentially a final check that the team is ready to begin the procedure

Sign out

- Ensure that a thorough and appropriate handover is given to the nursing staff to ensure safe ongoing care of the patient
- Complete a post-proning check of the patient to ensure all aspects of the post-proning care bundle are addressed

References

1. National Safety Standards for Invasive Procedures (NatSSIPs). NHS England Patient Safety Domain and the National Safety Standards for Invasive Procedures Group. 7th September 2015.
2. Smith G, Bamford P. LocSSIPs – The Quest to Improve Patient Safety. Journal of the Intensive Care Society 2017, Vol. 18(3) 180-183.

3. Proning Protocol

There is currently a lack of evidence for an optimal method of proning a patient. The following recommendations are therefore based on common themes that appear in the literature and intend to provide an example of safe and effective practice.

a. Indications

- Moderate to severe ARDS with PaO₂:FiO₂ ratio < 150 mmHg and FiO₂ ≥ 0.6
- Early within the course of the disease (ideally < 48 hours) following 12-24 hours of mechanical ventilation allowing for treatment optimisation.
- Best outcomes achieved using tidal volumes of 6ml/kg predicted body weight and consider the use of neuromuscular blocking drugs if there is evidence of ventilator dys-synchrony.

b. Contraindications

Absolute:

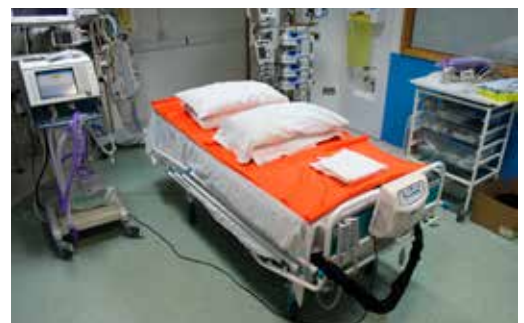- Spinal instability
- Open chest post cardiac surgery/trauma
- <24hrs post cardiac surgery
- Central cannulation for VA ECMO or BiVAD support

Relative:

- Multiple Trauma e.g. Pelvic or Chest fractures, Pelvic fixation device
- Severe facial fractures
- Head injury/Raised intracranial pressure
- Frequent seizures
- Raised intraocular pressure
- Recent tracheostomy <24hrs
- CVS instability despite resuscitation with fluids and inotropes
- Previously poor tolerance of prone position
- Morbid obesity
- Pregnancy 2nd/3rd trimester

c. Equipment

- Low air loss mattress/kinetic therapy bed or local equivalent
- Airway trolley
- Closed circuit suctioning
- Endotracheal tube (ETT) tapes
- Eye ointment
- Slide sheet
- x2 clean bedsheets
- x3-5 pillows
- ECG electrodes
- Absorbent pad



d. Preparation

Pre-Procedure

- Multidisciplinary discussion regarding the potential risks and benefits of prone ventilation
- Ensure no contraindications (See above)
- Inform and counsel patient/relatives if appropriate
- Inform Consultant and Senior Nurse on shift
- Ensure adequate numbers of staff available to facilitate safe procedure
- Ensure the team has considered any outstanding investigations, procedures and necessary transfers that would prove to be difficult to perform once the patient is prone

Airway/Breathing

- Difficult airway trolley checked and available. Note previous laryngoscopy grade and length of the endotracheal tube (ETT) at the lips
- Securely tape or tie the ETT, removing any anchor fast device. If tied then ensure padding in situ between tie and skin
- Suction oropharynx and airway prior to procedure
- Ensure closed circuit suctioning is available and working throughout procedure
- Patient should be pre-oxygenated with 100% O₂ and ensure appropriate ventilator settings. Note tidal volume and inspiratory pressure
- Perform pre-proning arterial blood gas and document results

CVS/Lines

- Ensure all lines are sutured and secured
- Discontinue non-essential infusions and monitoring
- Patient should be cardiovascularly stable. Prepare for post-proning instability with preparation of vasopressors/inotropes

Neuro:

- Patient should be receiving adequate sedation and analgesia. Deep sedation is usual (RASS score of -5)
- Consider muscle relaxation (Bolus dose may be required)

Skin/Eyes:

- Nursing staff to document skin integrity
- Eyes cleaned, lubricated and taped to prevent drying and ulceration. Ideally eyes should be protected with gel pad or similar

Tubes/Lines

- Nasogastric feed should be stopped, and the nasogastric tube aspirated (ideally at least 1hr before proning)
- Document NG length
- Chest drains need to be well secured and placed below the patient. Tubing should run down the patient and be managed by a separate team member. Clamp only if safe to do so.
- Adequate length on the remaining lines/cables running up the patient if above the waist, or down the patient if below
- Urinary catheter should be spigotted and taped to the inside of the leg

General

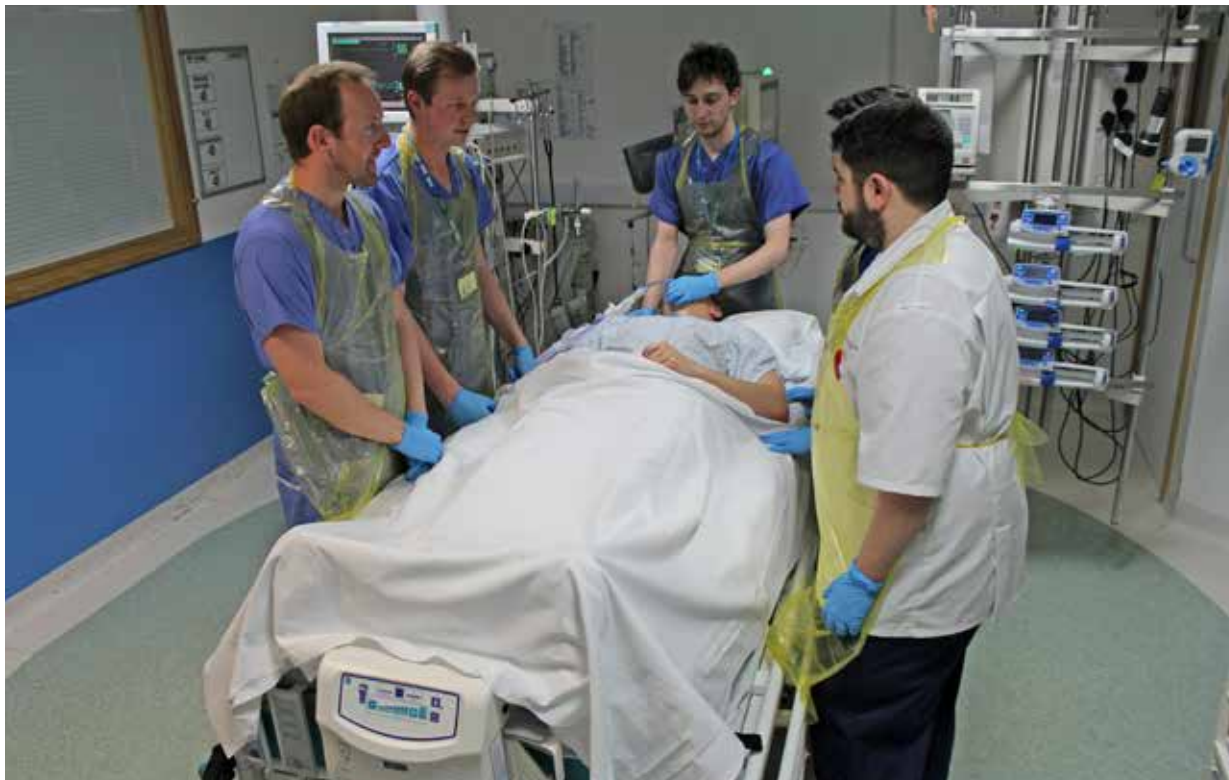- Daily hygiene addressed, eg. mouthcare, washing, dressing, changing of stoma bags
- Ventilator as close to the patient as possible on the appropriate side. The patient should be rolled towards the ventilator

4. Procedures

a. Supine to Prone

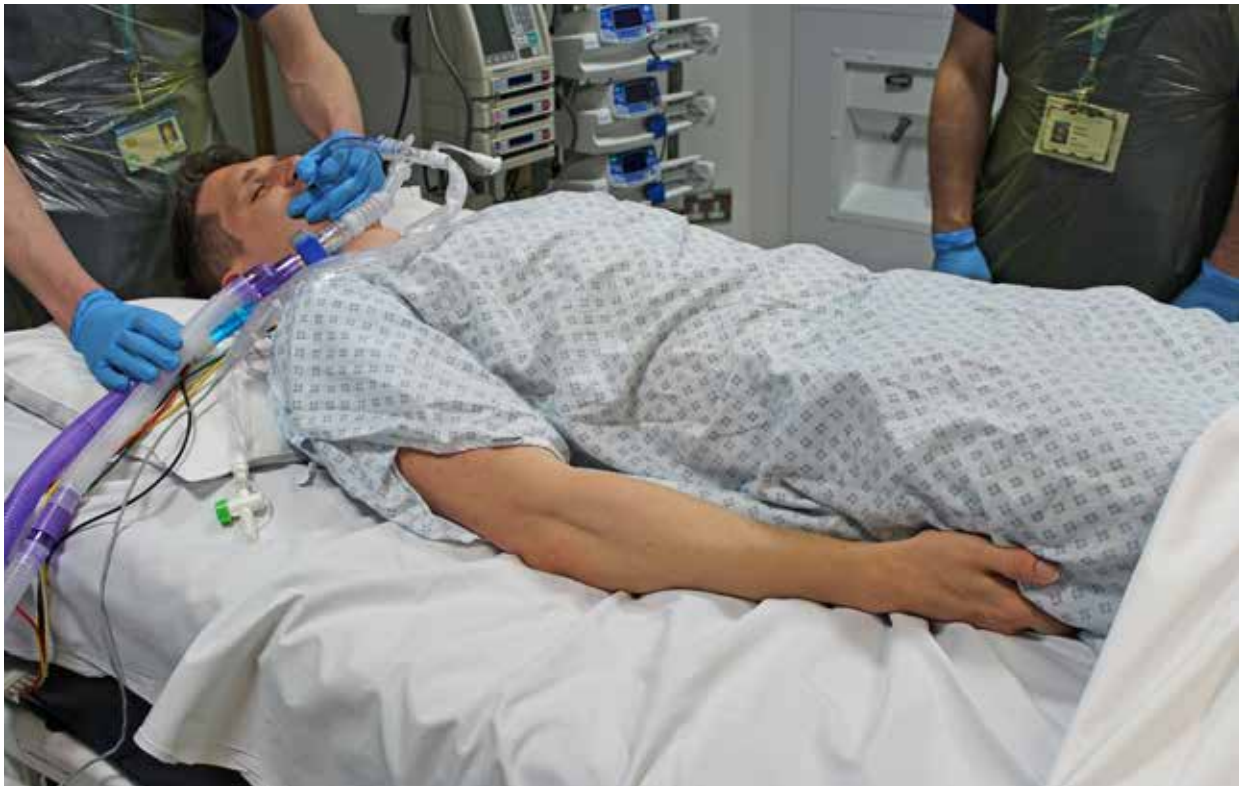Patients should be rolled towards the ventilator, ideally away from any central venous devices.

Step 1 – Staffing



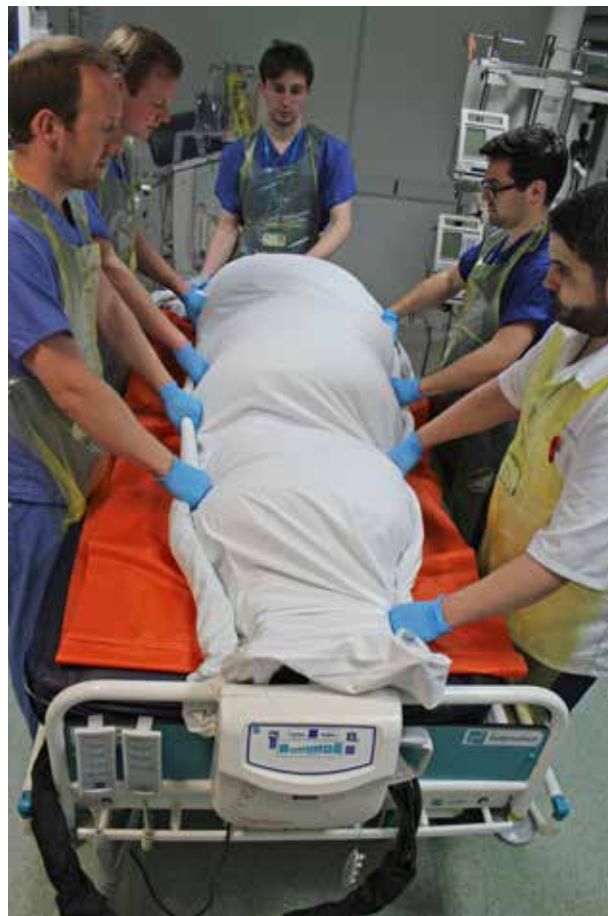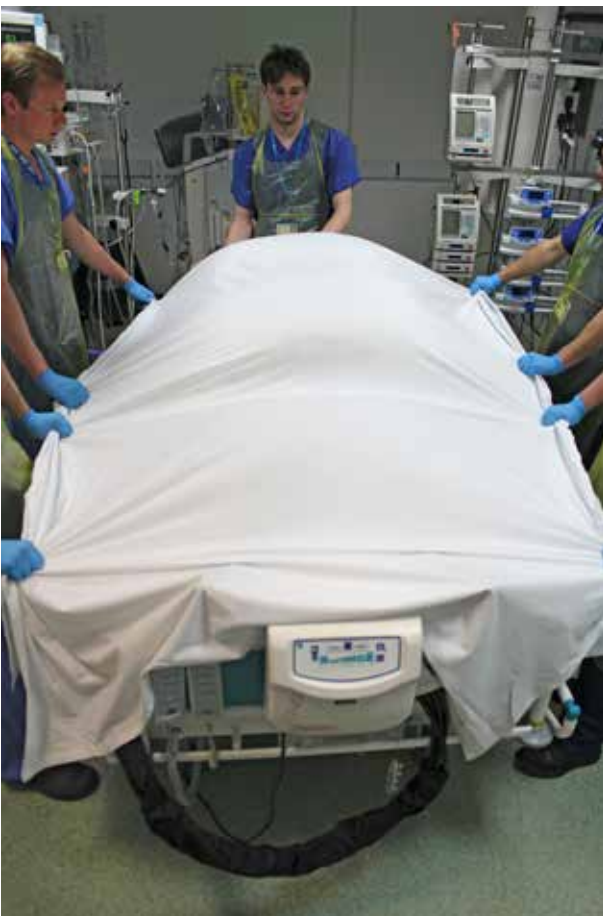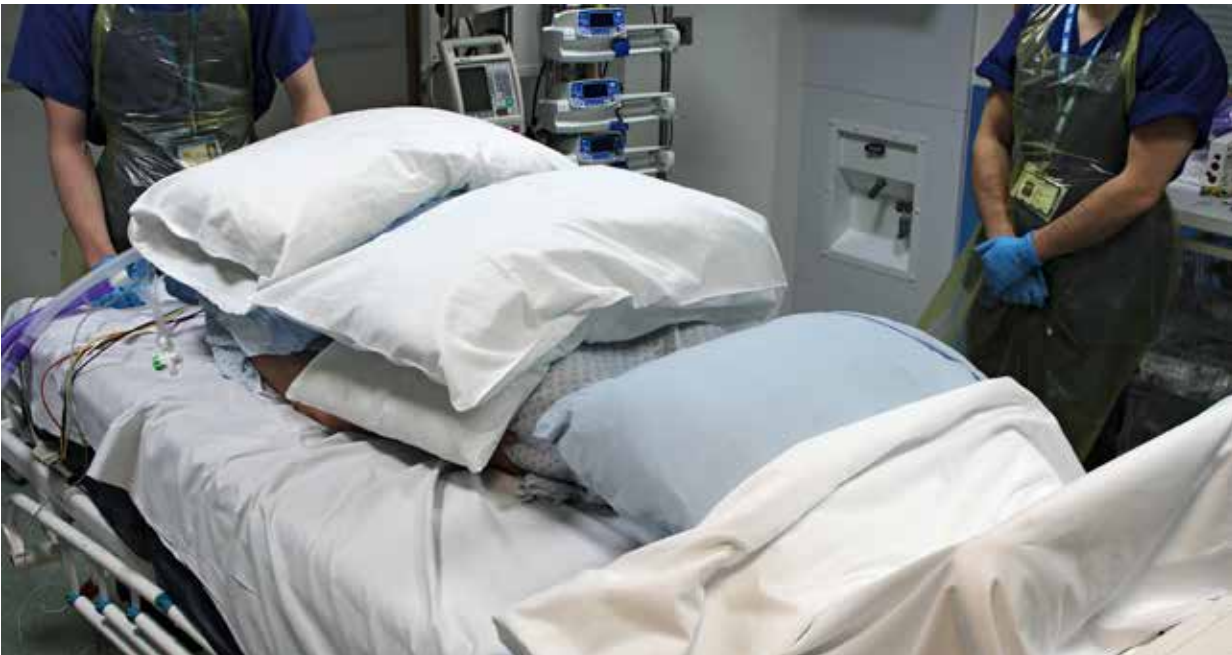- Minimum of 5 people including airway doctor
- Team members to introduce themselves and state their role
- Airway doctor positioned at head end and responsible for coordinating procedure
- At least two other people either side of the patient, but more may be required depending on the size of the patient
- Additional staff allocated to the management of chest drains/ECMO cannulas if in situ

Step 2 – Positioning

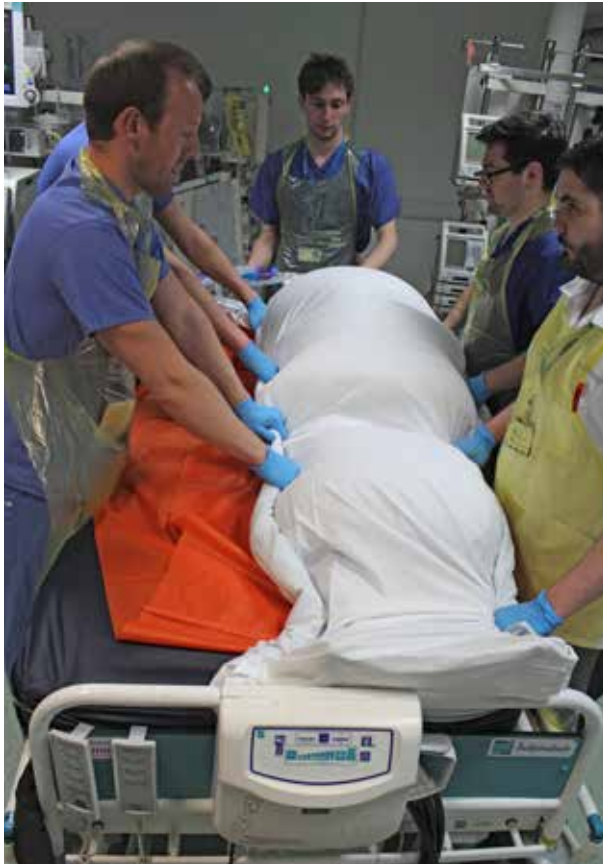

- Patient should be laid flat with the bed in a neutral position, on a clean sheet with a slide sheet beneath
- Arm closest to the ventilator is tucked underneath the buttock with the palm facing anteriorly (See diagram)
- Anterior ECG electrodes removed
- Pillows if required, can be placed over the chest, iliac crests and knees. They should be placed strategically, according to the patient's body habitus to reduce the pressure placed upon the abdomen

Step 3 – Patient wrapping

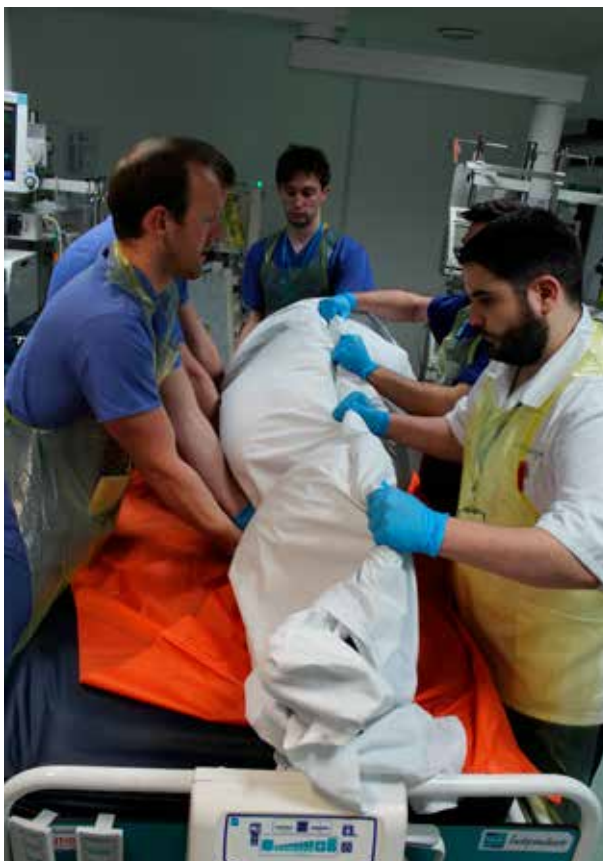

- A clean bed sheet should be placed on top of the patient leaving only the head and neck exposed
- The edges from the top and bottom bed sheets are rolled tightly together thereby encasing the patient between the two and keeping the pillows in the correct position on top of the patient



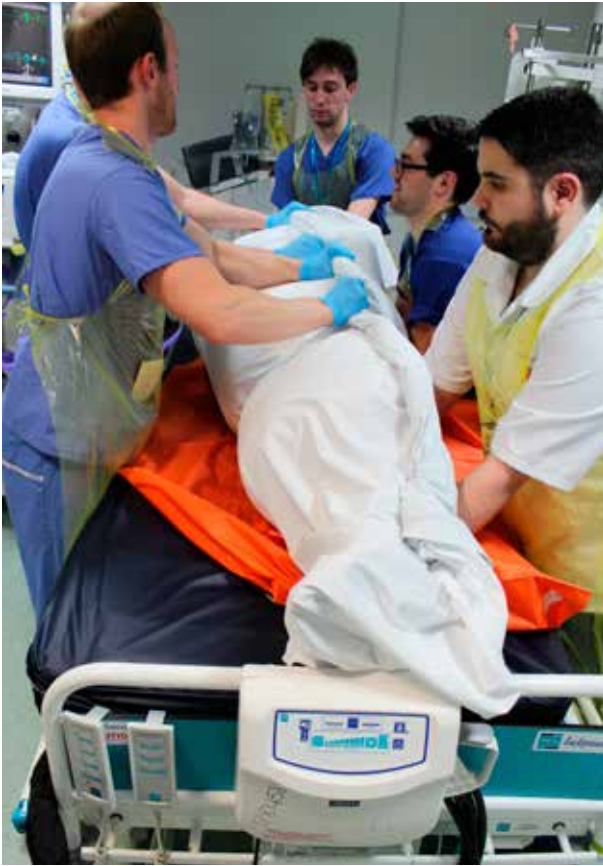Step 4 – Horizontal Move

- Keeping the bed sheets pulled taut and the edges rolled tight, the patient should be moved horizontally to lie on the edge of the bed
- The direction of the horizontal move should be away from the ventilator in the opposite direction to which the patient will be turned



Step 5 – Lateral turn

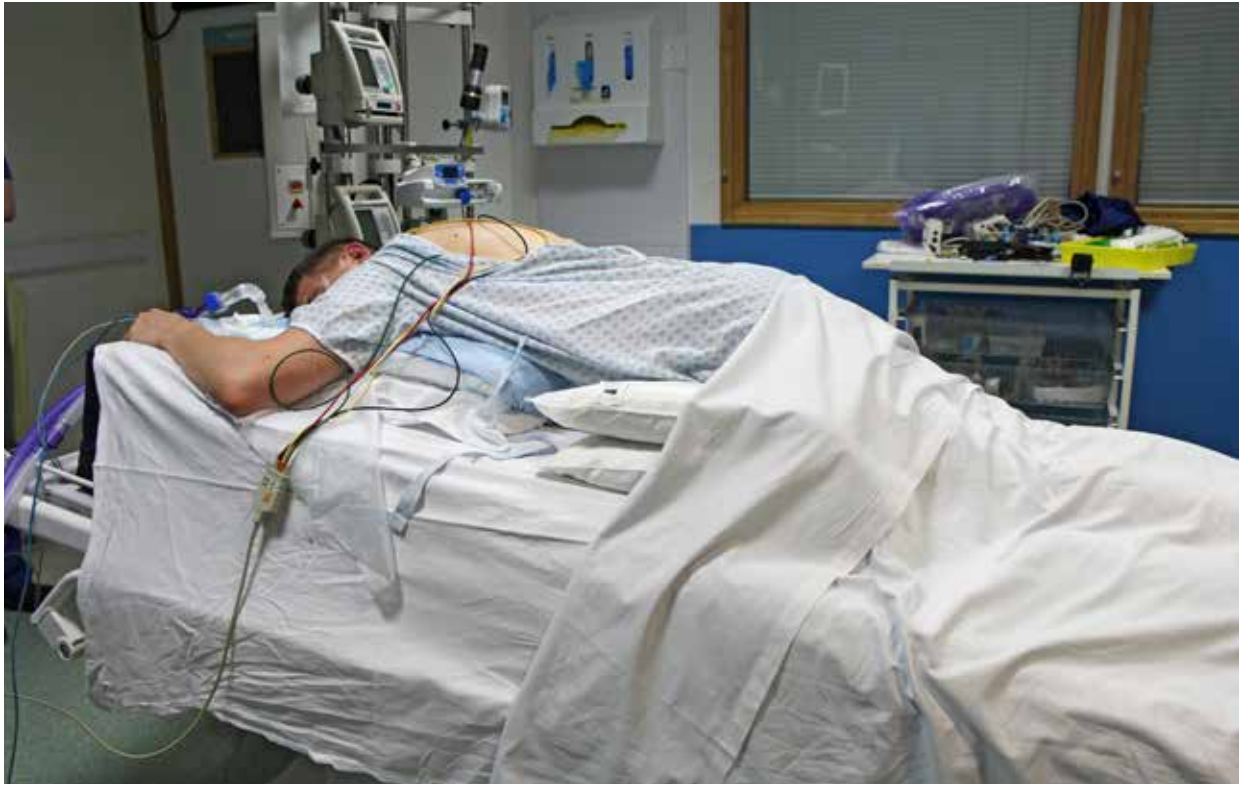- On the call of the person at the head end, whilst maintaining a tight grip on the rolled up sheets the patient is rotated 90° to lie on their side
- Staff on either side should then adjust their hand positions on the rolled up sheets, so that they now have hold of the opposite edge when compared to the horizontal move



Step 6 – Proning completion

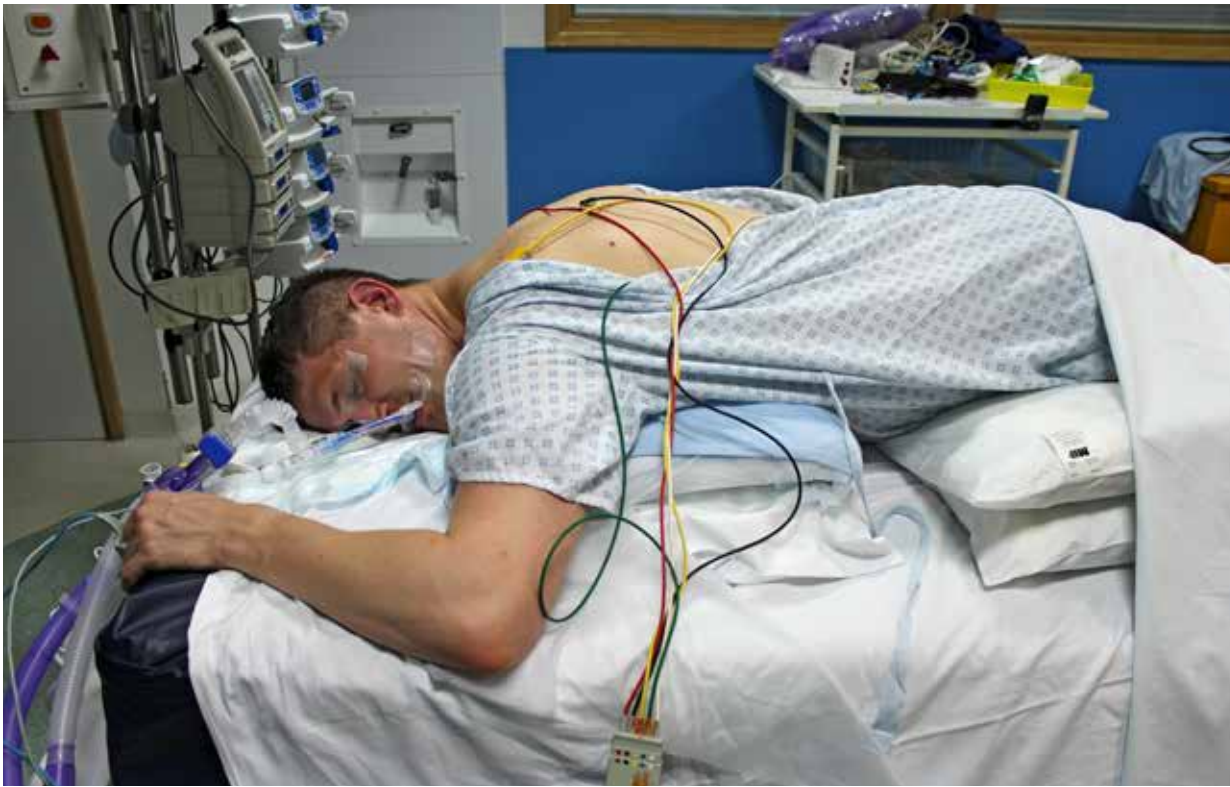- On the call of the person at the head end, the rolled up sheet is pulled up from beneath the patient whilst the patient is carefully turned into the prone position.
- Carefully support the head and neck and turn the head to face the ventilator as the patient is moved from the lateral to prone position.
- Ensure the ETT is not kinked and that a CO² trace is still present on the capnograph. Note the length of the ETT at the lips and review ventilator settings.
- Reattach the ECG electrodes and ensure all monitoring is re-established

Step 7 – Positioning



- Ensure the patient is in the centre of the bed and remove the slide sheet, ensuring counter traction on the patient to prevent them slipping off the bed
- Absorbent pad placed under patients head to catch secretions
- Carefully position the arms in the 'swimmers position'. This involves raising one arm on the same side to which the head is facing whilst placing the other arm by the patients side. The shoulder should be abducted to 80° and the elbow flexed 90° on the raised arm
- The position of both the head and arms should be alternated every two to four hours
- The patient should be nursed at 30° in the reverse trendelenburg position

Step 8 – Pressure Care



- Ensure optimal positioning of pillows tailored to the patient's body habitus
- Pressure areas should be meticulously checked
- No direct pressure on the eyes
- Ears not bent over
- ETT not pressed against the corner of the mouth / lips
- Nasogastric tube not pressed against nostril
- Penis hanging between the legs with the catheter secured
- Lines / tubing not pressed against the skin

b. Prone to Supine

- Airway trained doctor / adequate staff available
- Preparation as per proning;
 - Pre-oxygenate with 100% oxygen
 - Endotracheal tube and venous lines secure
 - Discontinue non-essential infusions / monitoring
 - Adequate sedation +/- muscle relaxation
 - Nasogastric feed stopped and nasogastric tube aspirated
 - Chest drains secure and below patient
- Patient wrapping as described – Horizontal move away from the ventilator so that the patient can be turned towards the ventilator.
- Ideally should be done in the morning; allows medical/nursing review, daily hygiene, physiotherapy and usually when most senior staff are present.

Emergencies

- Emergency 'de-proning' procedures should ideally be discussed before turning a patient prone.
- Emphasis should be placed on the protection of the ETT along with the safety of staff members.
- Turning a patient in an emergency without sufficient help risks further harm to both patient and staff.
- Cardiopulmonary resuscitation can be commenced in the prone position. (See below)
- Dislodgement of the endotracheal tube may be initially managed using a supraglottic airway device – Use of an i-gel may optimise insertion success in the prone position. ⁽¹⁾

References

1. Gupta B, Gupta S, Hijam B, Shende P, Rewari V. Comparison of three supraglottic airway devices for airway rescue in the prone position: A manikin-based study. J Emerg Trauma Shock. 2015;8:188–92

5. Nursing guidance for maintaining the patient in the prone position to prevent complications

The care of the prone patient requires attention to detail because relatively speaking it accounts for a small proportion of the patients nursed in critical care. The unfamiliarity with nursing patients in the position have led to our recommendation that a post-proning checklist should be made available for nursing staff to use. (See Appendix 2) This would ensure all appropriate measures are taken to reduce the risk of a complication arising due to the patient's position. The anticipation of complications is a key aspect of safety when nursing a patient in the prone position. The following recommendations are based on common themes through the literature and extensive experience in practice.

Patient positioning:

Having followed the above guidance on moving a patient from supine to prone the patient will finish on their front in the swimmers position. However, with patients being left prone for 16 hours or more there is a need to alter the patients positioning on a regular basis to prevent pressure damage from occurring.

This guideline therefore, advocates a change in the patient's head and arm position every 2-4 hours. ^(3,5)

Changing patients position:

Personnel: Minimum of three people required: an anaesthetist at head of bed to manage airway when changing head position and one person either side of the bed.

Bring the elevated arm to the patient's side; keeping the elbow at 90° and the palm facing the bed, bring the upper arm down so that it is alongside the chest. Turn the upper arm away from the body towards the legs so that the palm faces upwards at the same time as straightening the elbow. Rest the arm straight alongside the body.

Change the head position; with both arms now straight and alongside the patient's body, slide the patient up the bed so that the head is clear of the mattress. With the help of the other two staff, the anaesthetist can gently hold the head and ventilator tubing in order to turn the head to the other side. Adjust the head supporting aids accordingly. Slide the patient back down the bed so the head, is once again supported by the mattress. The method of changing the head position may vary and should be assessed on an individual patient basis.

Elevate the other arm; ensure that the palm of the hand that is to be moved is facing downwards into the bed. Keeping the upper arm against the chest wall, gently slide the hand upwards until there is 90° bend at the elbow. Maintaining the 90° bend and downward palm, gently slide the hand upwards until 80° abduction is achieved. ⁽¹⁾

Pillow positioning:

Position pillows:

- Across patient's chest - allowing breasts to be supported and free from pressure
- Across pelvis - ensuring abdomen to be free of compression
- Under shins - preventing hyper-extension at ankle and minimising pressure exerted on patient's knees

Alter height of pillows to ensure that neck and lower back are not hyper-extended
Position pillows in such a way, according to patient's size and body habitus to reduce risk of over distention by allowing the shoulders to fall slightly forward of the anterior capsule of shoulder joint, to reduce risk of brachial plexus injury.

Bed Position and Mattress:

Place bed in reverse trendelenberg position (30° head up)

- Minimises the development of facial oedema
- Reduces risk of NG feed refluxing into airway

Nurse patient on low air loss mattress and check mattress is working correctly prior to turning the patient prone. The authors acknowledge the variation in mattress use across intensive care units. It is therefore advisable to follow recommendations from the relevant hospital trust's manual handling department when using specialised beds or mattresses.

Eyes:

Patients nursed prone may suffer direct pressure on eyes or raised orbital/ophthalmic pressure due to gravitational effects or periocular swelling. This can cause

- Acute primary angle closure glaucoma
- Ischaemic optic neuropathy
- Vascular occlusion
- Orbital apex syndrome - visual loss from optic neuropathy with ophthalmoplegia involving multiple cranial nerves.

Therefore pressure needs to be taken off the eyes where possible. ⁽²⁾

Lightman & Montgomery suggest performing an eye assessment prior to proning; cleaning the eyes, apply eye ointment, covering with eye pads and securing with tape to prevent corneal abrasion. ⁽⁴⁾

Close lids, ensures lashes outside eye and lids free of ointment

Apply micropore tape horizontally

Always check corneal clarity with bright light: if not clear, alert medical staff

Assess eye condition 2-4 hourly ⁽⁶⁾

Keep patient normotensive, 30° foot down positioning (reverse Trendelenburg): to ensure good ocular perfusion pressure to adequately perfuse eyes.

Face:

Consider use of a fluidised positioner to create a channel for ETT to reduce the risk of pressure damage.

Monitor skin, including ears and nose. Ensure nasogastric tube is not pressing on inner nose or face. Ensure ears are not bent over.

ET Tube:

Check ET length prior to procedure/change ETT if tube short. Where possible ensure ETT is uncut to reduce pressure damage to mouth. Position ETT in middle of mouth, not compressing lips.

Place dermal pads between ETT cotton ties and patient's skin to reduce pressure from securing the ETT.

Monitor tightness of ETT cotton ties to reduce risk of pressure damage .

Check the ETT remains at the pre-prone depth.

Check ETT cuff pressure once patient prone.

Always ensure airway competent doctor present to secure ETT when turning patient's head to alternate swimmer's position.

Have ETCO₂ attached to ETT throughout procedure to monitor for disconnection of ventilator from ETT and dislodgement of ETT.

CVS stability

Re-attach all ECG monitoring and arterial catheter transducer as soon as possible once prone to enable resumption of haemodynamic monitoring. Ensure availability of vasopressor/fluid in case hypotension develops.

Genitals

Ensure male genitalia is positioned between patient's legs and catheter tube is free and between legs.

Lines/Drains

Restart all infusions and check the pump pressure to ensure no obstruction to flow.

Ensure all lines are secured properly prior to proning patient.

Consider replacement of CRRT line to appropriate site prior to proning patient (if possible), alternatively consider replacement following de-proning of patient.

Ensure no tubing running underneath patient.

Ensure chest drains patent and on correct degree of suction.

References

1. Galpin, M. (2014) Prone positioning in severe acute respiratory failure Salisbury NHS Foundation Trust: Integrated clinical information database
2. Grixti, A., Sadri, M., & Datta, A. (2012) Uncommon ophthalmologic disorders in intensive care unit patients *Journal of Critical Care* 27(6): 746.e9-746.
3. Harcombe, C. (2004) Nursing patients with ARDS in the prone position *Nursing Standard* 18(19): 33-39
4. Lightman, S., & Montgomery, H. (2017) *Ophthalmic Services Guidance: Eye Care in the Intensive Care Unit* London, ICS
5. Watling, G. (2016) *Guideline for Prone Ventilation in critical care unit at Colchester General Hospital* (version 1.6)
6. *Eye Care in the Intensive Care Unit*. June 2017. The Royal College of Ophthalmologists and Intensive Care Society

6. Special Circumstances

a. Prone positioning on ECMO

Introduction and background

Extra-corporeal membrane oxygenation (ECMO) describes an intervention that allows blood to be drained through a cannula placed in a central vein. A centrifugal pump then drives the venous blood through a membrane oxygenator which adds oxygen and removes carbon dioxide before the blood is returned to the body under pressure. If the blood is returned through another venous cannula, it is described as Respiratory, or Veno-Venous (VV) ECMO, supporting the functions of the lungs. If the return cannula is placed in a large artery then it is described as Cardiac, or Veno-Arterial (VA) ECMO, supporting the functions of the hearts and lungs.

A significant proportion of patients referred for VV ECMO will have already undergone prone positioning, either during escalation through local management protocols for the deteriorating respiratory failure patient, or on clinical advice from an ECMO centre. Once established on VV ECMO it is unusual for patients to be prone positioned. Aside from the additional risks associated with the ECMO circuit and cannulae, it is also rarely needed. This is because blood flows through the membrane oxygenator, commonly of up to 5 litres/minute, mean that it is normally possible to fully oxygenate and decarboxylate the majority of a patient's cardiac output. In this situation, the ECMO almost completely replaces a patient's lung function, and allows lung rest with minimal minute ventilation.

Indications for prone positioning on ECMO

There are three main situations when prone positioning may be considered during VV ECMO treatment:

- 1 - Refractory hypoxia on ECMO
- 2 - To facilitate pulmonary toilet and drainage
- 3 - Failure to wean VV ECMO

Of note, the only official guidance regarding prone positioning in ECMO comes from the Extra-corporeal Life Support Organisation (ELSO), which recommends consideration of proning on ECMO when there is posterior lung field consolidation with some lung fields open anteriorly ⁽¹⁾.

Refractory hypoxia on ECMO

One of the main potential benefits of respiratory ECMO is the ability to rest the lung, reducing ventilatory pressures and avoiding ongoing iatrogenic trauma. This is achieved by pressure-protecting ventilator settings, commonly accepting a small minute ventilation, with the extra oxygenation and decarboxylation requirements being undertaken by the ECMO. There are, however, circumstances where it is not possible to achieve ECMO flows that come close to matching the cardiac output. This may be because of patient physical and anatomical features restricting the size of either the drainage or return cannula, and therefore the amount of blood flow possible. It can also be because the patient has a high native cardiac output state, for example, high output sepsis. When this occurs, the increased fraction of cardiac output that bypasses the ECMO circuit can be considered shunt blood, and pulmonary gas exchange is required for oxygenation and decarboxylation. If it is not possible to increase ECMO blood flows, or reduce

a patient's cardiac output, the only alternative is to increase mechanical ventilation and inspired ventilator oxygen fraction. In severely diseased and poorly compliant lungs, prone positioning can then be considered to maximise pulmonary oxygenation and compliance, while still aiming to pressure protect the lungs.

Pulmonary Toilet and Drainage

There are some causes and contributors to acute severe respiratory failure that can necessitate VV ECMO support, and still produce a high output state in terms of pulmonary secretions. Examples may include after a severe pulmonary haemorrhage, or a pneumonia with extensive inflammatory exudate and sputum production. A stepwise approach involving suction, patient positioning, bronchoscopy and potentially one-lung ventilation (if unilateral pathology), can be considered. Depending on both clinical and radiological features, some patients, despite being on VV ECMO, will improve quicker and wean from ECMO sooner with postural drainage facilitated by the prone position.

Failure to wean VV ECMO

VV ECMO is often described as a way of pressing 'pause' on a rapidly deteriorating respiratory failure patient, buying time and preventing ongoing iatrogenic damage while the underlying cause for the respiratory failure is targeted and treated. As time on VV ECMO passes, the chances of significant complications related to the VV ECMO increase, including circuit and bleeding problems, as well as all the usual complications associated with a prolonged critical care admission. There may come a point in a respiratory ECMO patient's admission where they have failed to wean from ECMO support. The potential improvements in oxygenation and compliance with prone positioning may override the risks of proning in a patient who has not made significant progress. This decision should be taken after careful consideration of the individual circumstances of the patient.

Risks of Prone positioning on ECMO

All of the normal risks of prone positioning are present with the addition of ECMO specific risks. These specific risks include:

- The possibility of dislodging the ECMO cannulae
- Increased risk of air entrainment into the ECMO circuit
- Reduction in ECMO blood flows through compression of an ECMO cannulae and circuit tubing or through abdominal pressure changes
- Bleeding from cannulae sites that are no longer accessible
- Difficulty managing an oxygenator thrombosis that requires immediate circuit change.

Despite concerns about these complications, some of which would carry a high risk of morbidity and mortality, the published evidence suggests the risks are low and prone positioning is safe. A systemic review of seven studies of proned ECMO patients identified bleeding from cannulae sites in two studies and a single episode of air entrainment as the only complications in over 49 ECMO patients proned⁽²⁾. A recent published case series of 17 proned ECMO patients demonstrated one episode of oxygenator thrombosis and one episode of reduced blood flow which recovered, and no other complications⁽³⁾.

Practicalities and approach to Prone positioning on ECMO

The proning procedure for patients on ECMO should follow a similar approach to that of any other patient being prone. Priority should be on an adequate number of trained personnel and a structured checklist approach. As well as the normal number of people and roles required, there is an additional need, as a minimum, for a perfusionist or ECMO nurse to manage the ECMO console and pump, and a senior ECMO clinician to manage the cannulae and circuit during the prone positioning. Discussions should be had prior to proning of what to do in the event of an immediate ECMO related complication occurring. Volume infusions should be available if blood flows drop, and fluid resuscitation is required to improve ECMO drainage. All ECMO circuit tubing should be assessed if under the patient once prone, to ensure no compression that could reduce flows. Cannulae insertion sites should be carefully assessed prior to proning, and any bleeding managed prior to prone positioning. Careful positioning to avoid increases in intra-abdominal pressure once prone is needed to prevent reductions in inferior vena-cava ECMO drainage.

Conclusion

Prone positioning in patients on ECMO is an infrequent occurrence, but there are some indications where it should be considered. There are some additional risks and complexities, but the evidence suggests that these can be minimised and it is potentially a safe intervention. It is important that it takes place in a specialist ECMO centre with proning experience and protocols.

References

1. ELSO Adult Respiratory Failure Supplement to the ELSO General Guidelines, Version 1.3 Dec 2013 Page 3
2. Culbreth R, Goodfellow L; Complications of Prone Positioning During Extracorporeal Membrane Oxygenation for Respiratory Failure; A Systematic Review; Respiratory Care: 2016 Vol 6 No 2
3. Kimoun A, Roche S, Bridey C, Vanhuyse F, Fay R, Girerd N, Mandry D, Levy B; Prolonged prone positioning under VV-ECMO is safe and improves oxygenation and respiratory compliance; Ann. Intensive Care (2015) 5:35 p249-254

b. Flexible Bronchoscopy in the Prone Position

The role of flexible bronchoscopy in patients with lung parenchymal disease requiring mechanical ventilation is well established. Samples obtained from the bronchial tree provide diagnostic information which can be used to guide therapeutic interventions e.g. bronchoalveolar lavage. Suction of retained tracheobronchial secretions can ameliorate airway collapse and promote lung recruitment. Prone positioning may enhance mobilisation of bronchial secretions from the distal to proximal airways through postural drainage and recruitment of atelectatic lung¹. Impairment of ventilation may be seen if appropriate clearance is not achieved², in which case bronchoscopy may be indicated. To achieve benefit, it is recommended that mechanical ventilation in the prone position be delivered for at least 16 hours per day in moderate/severe ARDS³. Early termination of prone ventilation for bronchoscopy in the supine position may negatively impact the benefit derived from prone positioning.

Flexible bronchoscopy in this cohort of patients is particularly challenging due to severe hypoxia and the physiological consequences of introducing the flexible bronchoscope through the endotracheal tube. Partial obstruction of the endotracheal tube by the bronchoscope increases airway resistance producing undesirable effects on inspiratory and expiratory flows which

increase airway pressures and impair delivery of the tidal volume⁴. Modification of the ventilator settings is required to prevent hypoxia through de-recruitment and ameliorate hyperinflation and alveolar overdistension⁵. Unrecognised, this may lead to worsening of the lung parenchymal injury and possibly the development of life-threatening pneumothorax in diseased lungs⁶. Careful consideration is required with regard to the internal diameter of the endotracheal tube and external diameter of the selected bronchoscope⁷. The endotracheal tube diameter should be ≥ 1.5 mm greater than the bronchoscope.

There is a lack of information regarding the conduct and safety of flexible bronchoscopy in patients with moderate-to-severe ARDS who are mechanically ventilated in the prone position. A case report⁸ and case series⁹, totalling less than 10 patients, have suggested that flexible bronchoscopy in the prone position is feasible allowing therapeutic aspiration of airway secretions and collection of respiratory samples for diagnostic purposes. Performing bronchoscopy in brief sequential cycles with recovery periods may offset some of the negative physiological effects associated with the intervention in this patient group⁹. However, concerns regarding safety remain and warrant further evaluation⁴. A careful risk-benefit assessment should be undertaken prior to the decision to proceed with bronchoscopy in the prone position.

References

1. Gattinoni L, Taccone P, Carlesso E, et al. Prone position in acute respiratory distress syndrome. Rationale, indications, and limits. *Am J Respir Crit Care Med* 2013; 188(11): 1286-1293.
2. Graf J, Marini JJ. Do airway secretions play an underappreciated role in acute respiratory distress syndrome? *Curr Opin Crit Care* 2008; 14: 44-49
3. FICM/ICS Guideline Development Group. Guidelines on the management of acute respiratory distress syndrome. Version 1, July 2018.
4. Guillon A, Nay M-A, Kamel T. Flexible bronchoscopy-related safety in patients with severe ARDS. *Crit Care* 2018; 22: 166.
5. Lapinsky SE, Mehta S. Bench-to-bedside review: Recruitment and recruiting maneuvers. *Crit Care* 2005; 9: 60-65.
6. Nay M-A, Mankikian J, Auvet A, et al. The effect of fiberoptic bronchoscopy in acute respiratory distress syndrome: experimental evidence from a lung model. *Anaesthesia* 2016; 71: 185-191.
7. Du Rand IA, Blaikley J, Booton R, et al. British Thoracic Society guideline for diagnostic flexible bronchoscopy in adults. *Thorax* 2013; 68: i1-i44.
8. Guarracinoa F, Bertini P, Bortolotti U, et al. Flexible bronchoscopy during mechanical ventilation in the prone position to treat acute lung injury. *Rev Port Pneumol* 2013; 19(1): 42-44.
9. Kalchiem-Dekel O, Shanholtz C, Jeudy J, et al. Feasibility, safety, and utility of bronchoscopy in patients with ARDS while in the prone position. *Crit Care* 2018; 22: 54.

7. Cardiac arrest in the prone position

Early high quality chest compressions along with prompt defibrillation are of critical importance in optimising survival from cardiac arrest. Even short interruptions to chest compressions can adversely affect outcome and delay to defibrillation is related to reduced hospital survival. ⁽¹⁾

Whilst it may be easier to resuscitate somebody in the supine position, turning a critically ill prone patient in an emergency is associated with significant risk. There is the risk of displacement of the endotracheal tube, disconnection of vascular lines as well as injury to the patient and staff. The time delay associated with the procedure would also inevitably delay effective chest compressions and defibrillation.

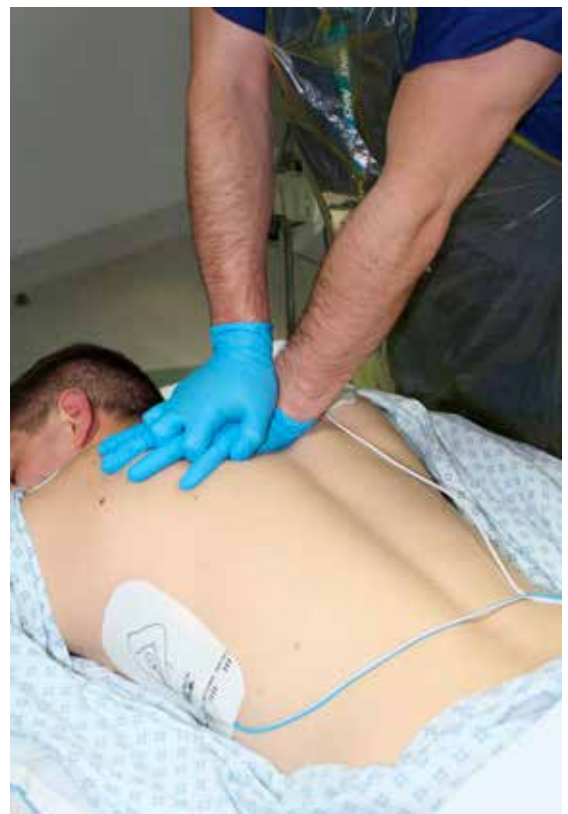The idea of prone cardio-pulmonary resuscitation (P-CPR) was first proposed by McNeil in 1989. ⁽²⁾ In 2001 Brown et al. published a systematic review of 22 case reports of CPR in proned positioned patients, 10 of which survived to discharge. ⁽³⁾ In 2003 Mazer et al. demonstrated that P-CPR generated a higher systolic and mean arterial pressure during circulatory arrest in ICU patients than standard CPR ⁽⁴⁾, with similar results again published by Wei et al. in 2006. ⁽⁵⁾

Resuscitation Council (UK) guidelines published in 2014 recommend that chest compressions should be started without any initial change in position in adult patients who have a cardiac arrest during neurosurgery. ⁽⁶⁾ It is recommended that the efficacy of CPR should be judged using the end-tidal CO₂ and arterial pressure and waveform, with the patient turned supine if chest compressions are judged to be ineffective.

The 2010 American Heart Association guidelines for cardiopulmonary resuscitation and emergency cardiovascular care recommend that 'when the patient cannot be placed in the supine position, it may be reasonable for rescuers to provide CPR with the patient in the prone position, particularly in hospitalized patients with an advanced airway in place'. ⁽⁷⁾

Chest Compressions

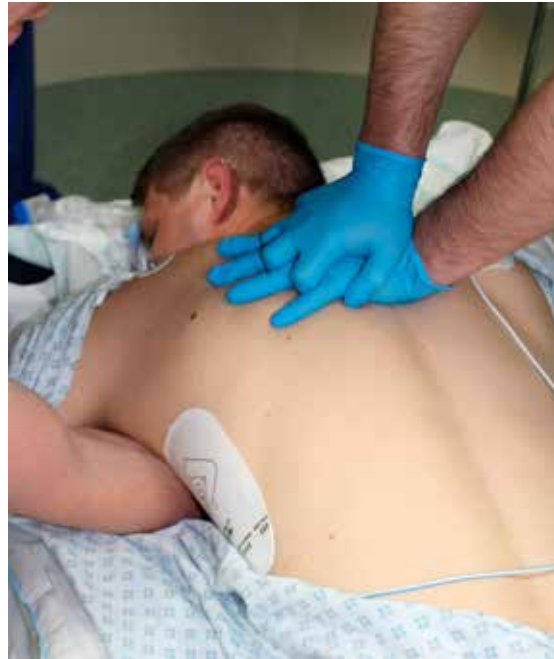There is little good evidence to guide the optimum position for chest compressions in the prone patient. The Resuscitation Council and American Heart Association make no specific recommendation as the majority of evidence comes from individual case reports. The first case reports of successful prone CPR were published in 1992 by Sun et al. They reported two successful resuscitations of prone neurosurgical patients using 'reversed precordial compression'. They recommended chest compressions over the mid-thoracic spine using a hand under the lower sternum as counter-pressure. ⁽⁸⁾ In 1996 Dequin et al. reported successful prone CPR in an ICU patient with severe pneumonia, reporting two-handed chest compression over the mid-thoracic spine with a second person providing counter-pressure under sternum. ⁽⁹⁾ Gomes et al. have reported a successful case of prone CPR in a neurosurgical patient, using chest compression over the mid-thoracic level but



7. Cardiac arrest in the prone position

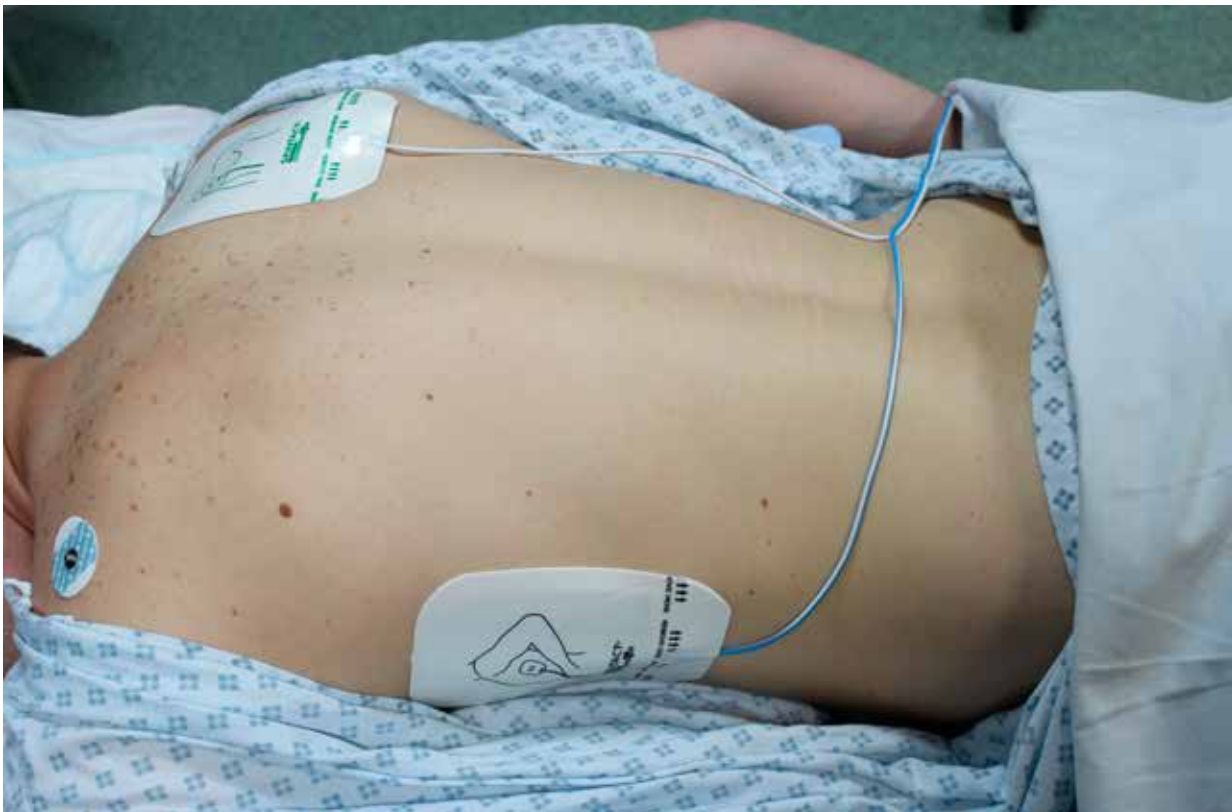without sternal counter-pressure. ⁽¹⁰⁾ A recent study published by Kwon et al. retrospectively reviewed the chest computed tomography images of 100 prone patients and defined the optimum landmark for prone CPR as the region which correlates with the largest left ventricular (LV) area. They concluded that the largest LV cross-sectional area is 0 to 2 vertebral segments below the inferior angle of the scapula in at least 86% of patients, although further studies are needed to determine whether this position is optimal for chest compressions in the prone position. ⁽¹¹⁾

Taking into account the limited evidence available, we recommend a two-handed technique for chest compressions over the mid-thoracic spine located between the two scapula. Counter-pressure may be applied using a second person.



Defibrillation

Successful defibrillation can be achieved with the pads either applied postero-lateral (one in the left mid-axillary line, the other over the right scapula) or in the bi-axillary positions. See photo below. ⁽⁶⁾



References

1. Zhan L, Yang LJ, Huang Y, He Q, Liu GJ. Continuous chest compression versus interrupted chest compression for cardiopulmonary resuscitation of non-asphyxial out-of-hospital cardiac arrest (Review) Cochrane Database of Systematic Reviews 2017, Issue 3. Art. No: CD010134
2. Re-evaluation of cardiopulmonary resuscitation. *Resuscitation* 1989;18:1–5.
3. Brown J, Roger J, Soar J. Cardiac arrest during surgery and ventilation in the prone position: a case report and systematic review. *Resuscitation* 2001;50:233–8.
4. Mazer SP, Weisfeldt M, Bai D, Cardinale C, Arora R, Ma C, Sciacca RR, et al. Reverse CPR: a pilot study of CPR in the prone position. *Resuscitation* 2003;57:279–85.
5. Wei J, Tung D, Sue SH, Wu SV, Chuang YC, Chang CY. Cardiopulmonary resuscitation in prone position: A simplified method for outpatients. *J Chin Med Assoc* 2006;69:202-6.
6. Resuscitation Council (UK) to produce its Management of cardiac arrest during neurosurgery in adults guidance. Accreditation is valid for 5 years from March 2015.
7. 2015 American Heart Association guidelines update for Cardiopulmonary Resuscitation and emergency cardiovascular care. *Circulation* 2015; 132:18: Supplement 2.
8. Sun W, Huang F, Kung K, Fan S, Chen T. Successful Cardiopulmonary resuscitation of two patients in the prone position using reversed precordial compression. *Anesthesiology* 1992;77(1):202–4.
9. Dequin P-F, Hazouard E, Legras A, Lanotte R, Perrotin D. Cardiopulmonary resuscitation in the prone position: kouwenhoven revisited. *Intensive Care Med* 1996;22:1272.
10. Gomes D de S, Bersot CDA. Cardiopulmonary resuscitation in the prone position. *Open Journal of Anesthesiology* 2012; 2: 199-201
11. Kwon MJ, Kim EH, Song IK, Lee JH, Kim HS, Kim JT. Optimizing prone cardiopulmonary resuscitation: Identifying the vertebral level correlating with the largest left ventricle cross-sectional area via computed tomography scan. *Anesth Analg* 2017;124:520-3.

Appendix 1. LocSSIP PROCEDURE SAFETY CHECKLIST: Prone Ventilation in Critical Care

BEFORE THE PROCEDURE	
Have all members of the team introduced themselves?	Yes No
Consultant/Senior nurse aware	Yes No
Any contraindications	Yes No
Re-intubation equipment available	Yes No
Eyes taped and lubricated	Yes No
ETT taped/tied (ETT anchor devices removed)	Yes No
Stop NG feed and aspirate NGT	Yes No
Non-essential monitoring + infusions discontinued	Yes No
Adequate length on remaining lines going either up or down bed	Yes No
Chest drains below patient/clamped only if safe to do so.	Yes No
Assess and document skin integrity	Yes No
Anti-pressure dressings to bony prominences/nipples	Yes No
Daily hygiene completed (ie. mouthcare/washing/dressings etc.)	Yes No
Equipment available as per guideline	Yes No
Are there any concerns about this procedure for the patient?	Yes No
Concerns	

TIME OUT	
Verbal confirmation between team members before start of procedure	
Minimum of 5 people plus 1 for chest drains	Yes No
All team members aware of role	Yes No
Appropriate ventilator settings	Yes No
Cardiovascular stability	Yes No
Adequate sedation (ie. RASS -5)	Yes No
Adequate muscle relaxation – consider need for bolus	Yes No
Pillows positioned correctly – chest, pelvis, knees	Yes No
Team members familiar with procedure	Yes No

Patient Sticker

SIGN OUT	
ETT length at teeth/Capnography	Yes No
Monitoring re-established	Yes No
Ventilator settings reviewed	Yes No
Lines secured	Yes No
Chest drains below patient + unclamped	
Pressure areas checked	
- ETT not pressing against lips	
- No pressure on eyes	
- Ears not bent over	
- NG not pressed against nose	Yes No
- Penis between legs + urinary catheter secured	
- Lines / tubing not resting against skin	
- Pillows positioned correctly	
Slide sheet removed and reverse trendelenburg 30 °	Yes No
NG position confirmed and resume enteral feed	Yes No
Post-proning care bundle available	Yes No

PaO2/FiO2 Ratio	
Grade Laryngoscopy	
Length ETT at teeth	
Length NGT at nostril	
Airway Doctor	
Consultant in charge	



The Faculty of
Intensive Care Medicine

Signature of responsible person completing the form	
Procedure Date + Time	

Appendix 2. Post Proning Nursing Checklist

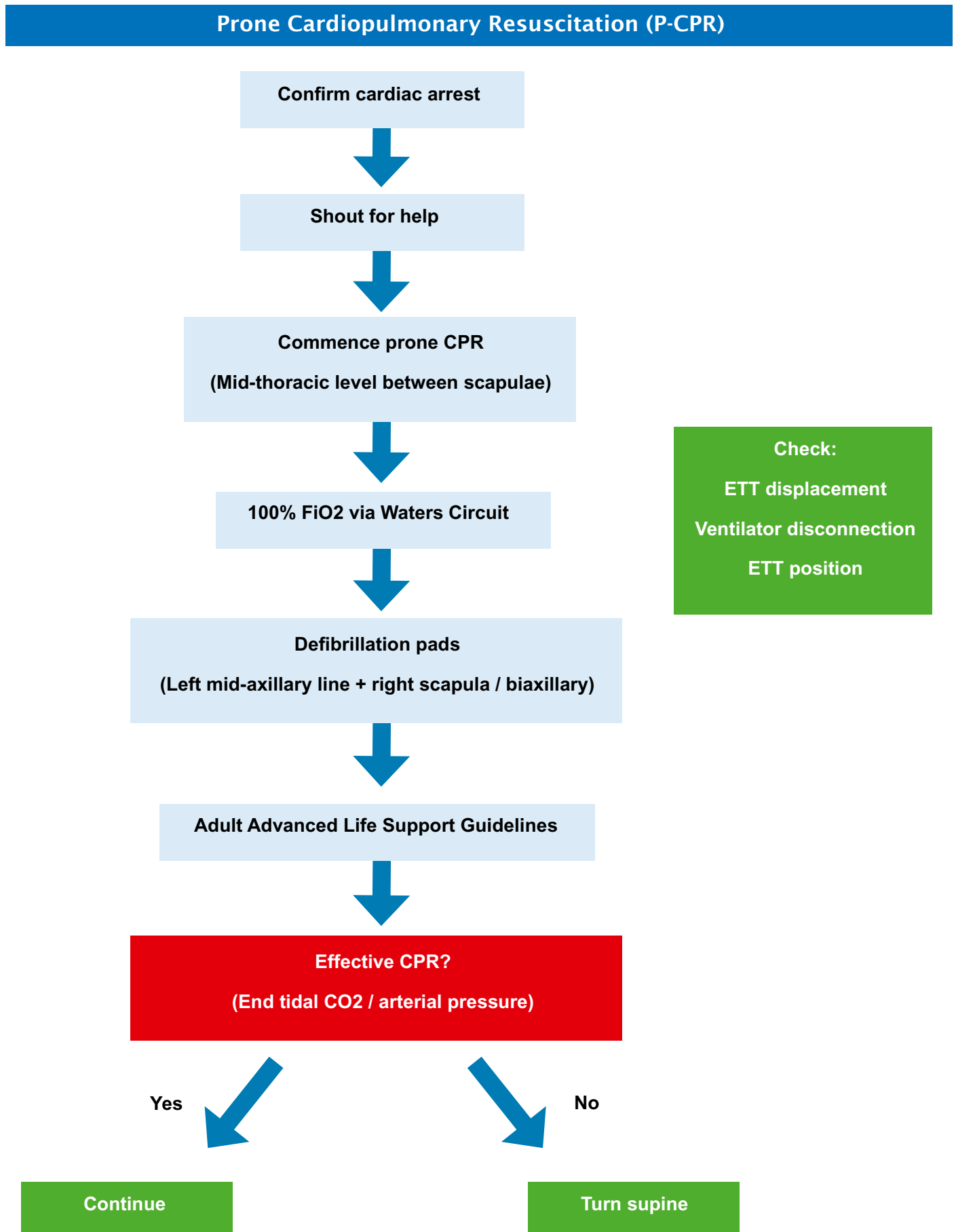
Checklists are among the many tools used in practice to improve patient safety and reduce complications. Use of a post proning checklist is aimed at reducing subsequent complications from being nursed prone. This is an example of a post proning checklist for use by nursing staff. Checklists should be unit specific and need to be modified, in response to patient safety issues logged at that unit.

Area	Check Point	Checked --Initial--
Head/Face	Check ETT/tracheostomy is accessible/not kinked (ETT cm at teeth)	
	All connections between ETT and ventilator circuit secure	
	Note ETT/tracheostomy cuff pressure	
	ETT positioned in middle of mouth, not compressing lips	
	Dermal gel pads placed between ETT cotton ties and patient's skin	
	Confirm ears are not bent over	
	Perform ETT/tracheal suctioning immediately post proning	
	Eyes taped shut	
	No direct pressure on the eyes	
	Ensure 30° foot down positioning (Reverse Trendelenburg)	
	Move patient's head from side to side 2 hourly to relieve pressure	
	NG tube secure and not displaced (cm at nose=.....)	
	NG tube not causing pressure to nostril	
Neck	Verify that patient's lower back and neck are not hyper-extended	
	Front of neck free from compression	
	Central line secure	
Chest	Chest drains patent and on correct suction	
	Breasts supported and free from pressure	
Abdomen	Abdomen free	
Pelvis	Pelvis support cushion in place	
	Male genitalia positioned between legs	
	Catheter tubing is free and between legs	
Arms	Placed by side of patient	
	Shoulders not rotated	
	No compression over elbows	
	Wrists in neutral position	
	Hands free	
	Alternate Swimmers Position 2-4 hourly	
	No peripheral IV lines under patient	
Legs	Pillows positioned under shins to prevent extension	
Infusions/Monitoring	All monitoring recommenced	
	All infusions connected and infusing	
	Check CRRT lines patent	
	ECG leads not underneath patient	
	Ensure patient is well sedated and pain free	
	Infusion lines not resting on patient's skin	
	Mattress is in dynamic mode	
	Check ABG 20-30 mins post prone positioning	



Lined area for writing notes.

**Appendix 3.
Prone Cardiac Arrest Flowchart**





A series of horizontal lines providing space for notes.

Intensive Care Society | Churchill House | 35 Red Lion Square | London | WC1R 4SG
T: +44 (0)20 7280 4350 E: info@ics.ac.uk W: www.ics.ac.uk

Registered as a Company limited by Guarantee
Registered No: 2940178 (England) Registered Office as above
Registered as a Charity in England and Wales No: 1039236 and in Scotland No: SC040052
© Intensive Care Society